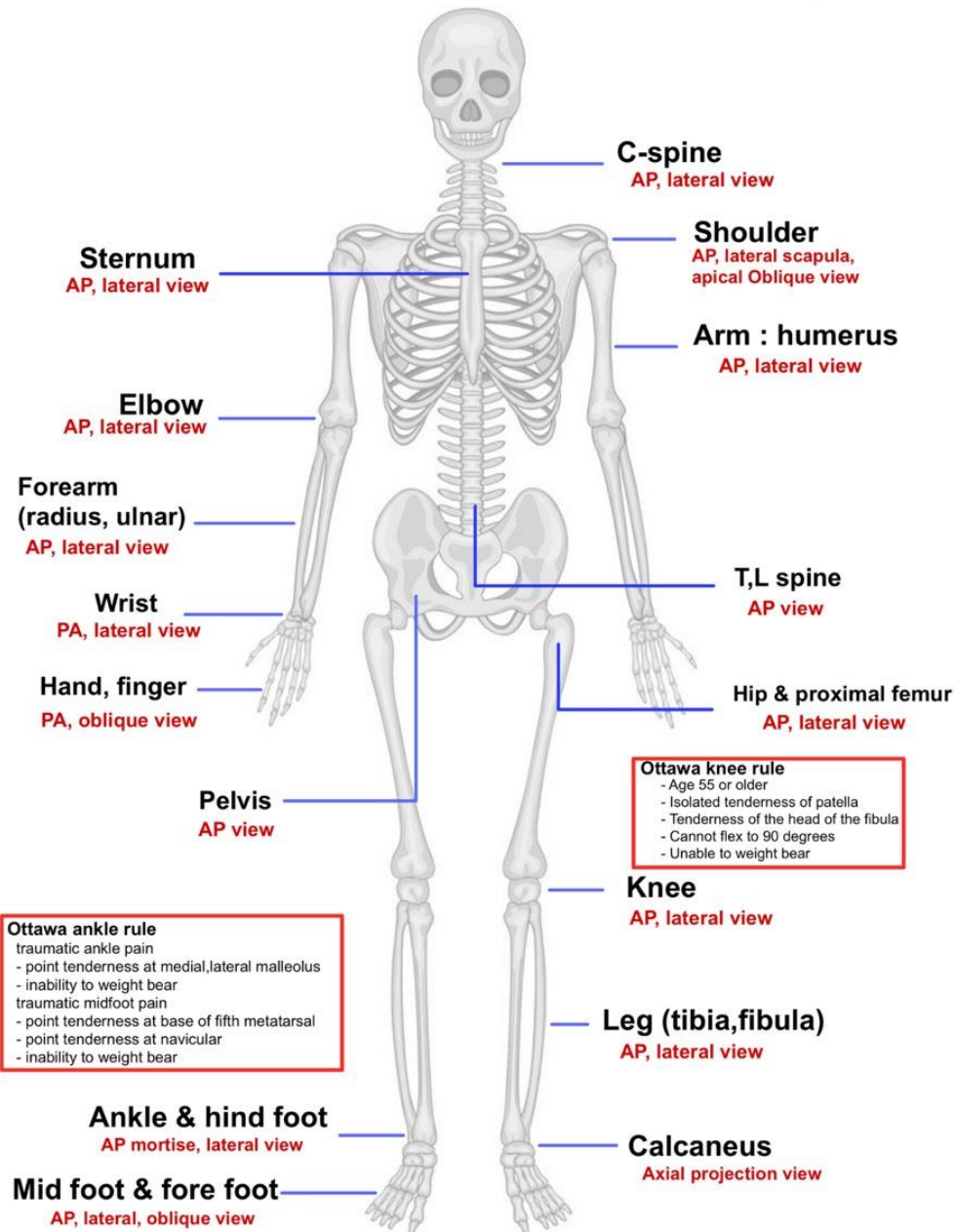
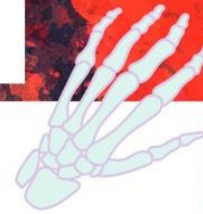

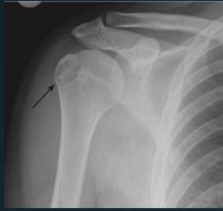# FILM XRAY GUIDE



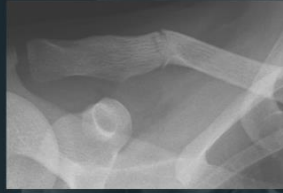**Ottawa ankle rule**  
 traumatic ankle pain  
 - point tenderness at medial, lateral malleolus  
 - inability to weight bear  
 traumatic midfoot pain  
 - point tenderness at base of fifth metatarsal  
 - point tenderness at navicular  
 - inability to weight bear

**Ottawa knee rule**  
 - Age 55 or older  
 - Isolated tenderness of patella  
 - Tenderness of the head of the fibula  
 - Cannot flex to 90 degrees  
 - Unable to weight bear

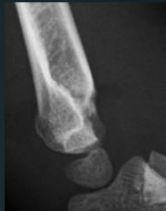# COMMON FRACTURE



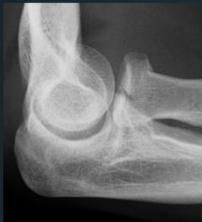Fx of Greater tuberosity of humerus



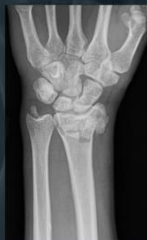Fx middle third of clavicle



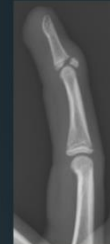Ped : Supracondylar Fx  
c posterior displacement



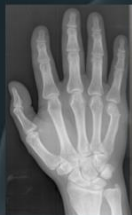Fx of head and neck of radius



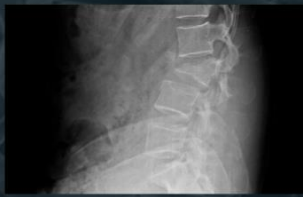Fx of distal end radius c Fx distal ulna



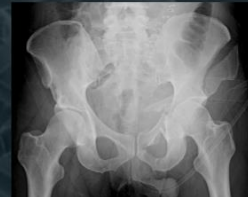Fx base of phalanx



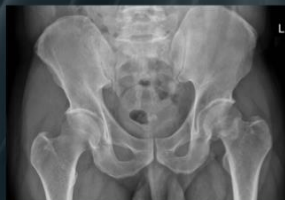Fx of metacarpal neck  
Boxer's fracture



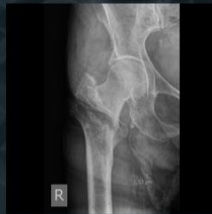Compression Fx of vertebra



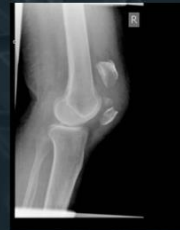pubic ring Fx



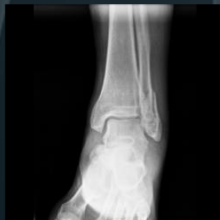Femoral neck Fx



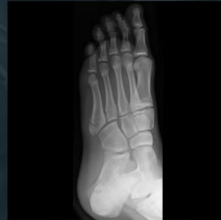intertrochanteric Fx



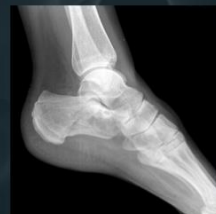patella Fx



lateral malleolus Fx



Fx Base of 5th metatarsal



calcaneus Fx