



## OPERATIVE NOTE FOR TIBIAL SHAFT FRACTURE

### ภาควิชาออร์โธปิดิกส์ โรงพยาบาลเชียงรายประชานุเคราะห์

Date of Operation..... Time started ..... Time ended.....  
 Surgeon.....First Assistant..... Second Assistant.....  
 Scrub Nurse.....Circulating Nurse.....  
 Clinical Diagnosis: Closed Open fracture shaft of  left  right tibia.  
 Postoperative Diagnosis: Closed Open fracture shaft of  left  right tibia.  
 Operative Procedure  Debridement Close reduction Open reduction, and internal fixation  
 with  Plate and screws  Others.....  
 Anesthesia.....Anesthetist.....

#### Description of Operation

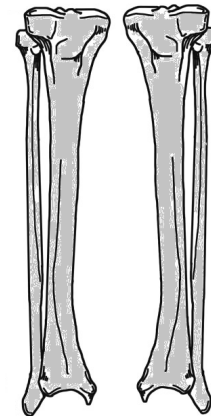
**Position:** Supine .....

**Incision:** Approach: Anterolateral  Anteromedial  MIPO Nailing

**Finding:** Simple Comminuted Segmental Wedge Spiral Oblique Transverse fracture

**Procedure:**

- Surgical wound was incised layer by layer
- Fracture site was exposed.
- Length and rotation were restored by manual traction.
- Lag screws were inserted.
- .....
- Reduction was done and fixed with .....
- .....
- .....
- Fluoroscopic image was done.
- Surgical wound was irrigated.
- Drain was placed
- .....
- Skin was closed by Nylon Staple



Right

Left

Please draw fracture line and implant

Complication: None  .....

Tissue sent for pathology: Yes  No

Estimate Blood Loss ..... ml Doctor's signature.....

Wound classification:  Clean  Clean contaminated  Contaminated  Dirty

ติด Sticker ผู้ป่วย