



OPERATIVE NOTE FOR INTERTROCHANTERIC FRACTURE
ภาควิชาออร์โธปิดิกส์ โรงพยาบาลเชียงรายประชานุเคราะห์

Date of Operation..... Time started Time ended.....
 Surgeon.....First Assistant..... Second Assistant.....
 Scrub Nurse.....Circulating Nurse.....
 Clinical Diagnosis: Closed intertrochanteric fracture : left right femur
 Post-Operative Diagnosis: Closed intertrochanteric fracture : left right femur
 Operative Procedure Close reduction Open reduction, and internal fixation with
 Cephalomedullary nail Others.....
 Anesthesia.....Anesthetist.....

Description of Operation

Position: Supine on Fracture Table

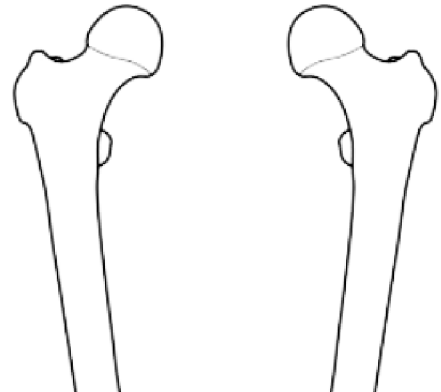
Incision: Lateral approach

Finding: Stable fracture pattern Unstable intertrochanteric fracture [check below]

- Large posteromedial comminution Subtrochanteric fracture
 Reverse obliquity fracture Fracture or thin lateral cortex

Procedure:

- Close reduction was done under fluoroscopy.
- Lateral skin incision. Guidewire was placed.
-
- PFNA nail sizewas inserted.
- Hip Blade sizewas inserted.
- Distal screw was inserted.
- Proximal end cap was inserted.
- The final position of the nail is checked in two planes under fluoroscopy.
- Surgical wound was irrigated.
- Drain was placed.
- Skin was closed by Nylon Staple.



Right

Left

Please draw fracture line and implant

Complication: None

Tissue sent for pathology: Yes No

Estimate Blood Loss ml Doctor's signature.....

Wound classification: Clean Clean contaminated Contaminated Dirty

ติด Sticker ผู้ป่วย