



## OPERATIVE NOTE FOR DISTAL RADIUS FRACTURE (CRIF + K-WIRES)

### ภาควิชาออร์โธปิดิกส์ โรงพยาบาลเชียงใหม่ประชานุเคราะห์

Date of Operation..... Time started ..... Time ended.....  
 Surgeon.....First Assistant..... Second Assistant.....  
 Scrub Nurse.....Circulating Nurse.....  
 Clinical Diagnosis:Closed Open : left  right distal radius.  
 Post-Operative Diagnosis:Closed Open : left  right distal radius.  
 Operative Procedure  Close reduction  Open reduction, and internal fixation with  
 K-wires  Others.....  
 Anesthesia.....Anesthetist.....

#### Description of Operation

**Position:** Supine.

**Incision:** None .....

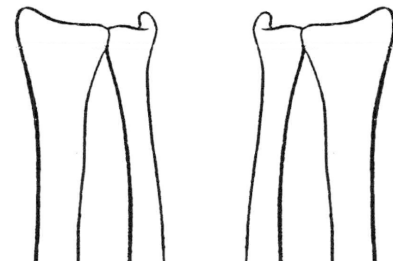
**Finding:** Radius: simple  comminuted

Extra articular  partial articular  complete articular fracture

Ulna: simple  comminuted  Ulnar styloid fracture

**Procedure:**

- .....
- Close reduction by longitudinal traction and manual reduction.
- Reduction was checked under fluoroscopy.
- .....
- ..... (Number of) K-wires were inserted.
- .....
- The positions of the k-wires were checked in two planes under fluoroscopy.
- .....
- Drain was placed.
- Skin was closed by Nylon Staple.
- Short arm Long arm slab  cast was applied.



Right

Left

Please draw fracture line and implants

Complication: None  .....

Tissue sent for pathology: Yes  No

Estimate Blood Loss ..... ml Doctor's signature.....

Wound classification:  Clean  Clean contaminated  Contaminated  Dirty

ติด Sticker ผู้ป่วย